ARCHITECTING THE OCCLUSAL PLANE

Clayton A. Chan, D.D.S., M.I.C.C.M.O
Director of Neuromuscular Dental Studies, Las Vegas Institute for Advanced Dental Studies

It is known that dental occlusion is influenced by changes in the cant of the occlusal plane. Studies have defined the geometric and mathematical relationships between dental occlusion and rotations of the occlusal plane in the sagittal view. As a general clinical guide, each degree of rotation of the occlusal plane will result in a half millimeter change in the dental occlusal relationship. This is of importance, because changes in the cant of the occlusal plane are sometimes unintentional, as well as intentional, during occlusal therapy. Earlier studies have also documented that the occlusal plane rotates naturally upward and forward approximately 6 degrees during growth and development. This phenomenon tends to develop a Class II dental relation and therefore has important implications for the developing dentition.<1>

Establishing a proper maxillary mounted study cast is critical in designing the aesthetic smile profile. Clinical experience and many studies have shown that the manner in which the maxillary cast is mounted and oriented to a horizontal occlusal plane will affect the appearance of the smile - a broad toothy look or a soft gentle smile. New trends in restorative dentistry indicate that dentist and technicians are using horizontal reference tables and leveling planes rather than traditional ear bow transfers to relate the maxillary cast for diagnostic wax ups and smile designing. Using any Fox Occlusal Plane plate (Dentsply, International) allows for very simple transmitting of facial and functional information to the articulator.

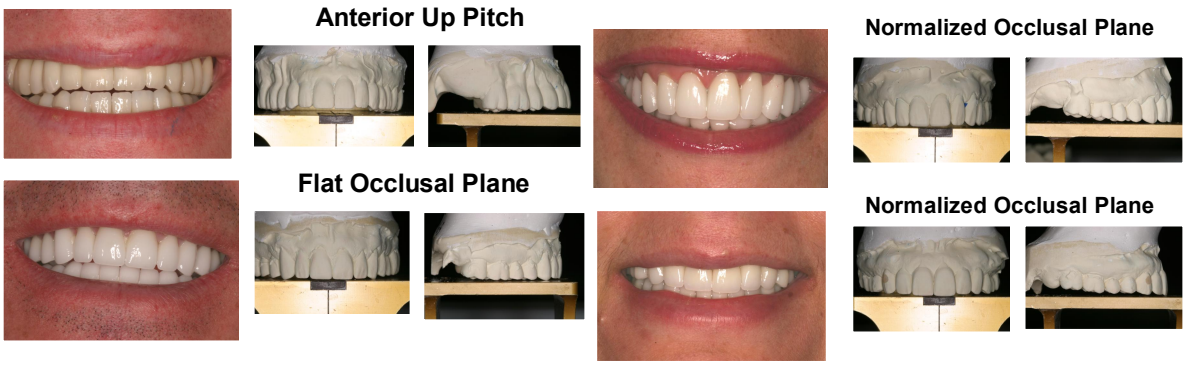

A. B.

Group A: Show broad toothy smiles. Maxillary casts were mounted to soft tissue hamular notch-incisive papilla (HIP) landmarks. Note the occlusal plane is flat and anteriorly pitched upward. Group B: Shows softer gentle smiles. Maxillary casts also mounted to HIP, shows a downward occlusal plane slant – physiologic occlusal plane orientation.

Relating the Maxillary Arch to the Cranium

There are many reference planes the restorative and orthodontic clinician uses in the assessment of the maxillary arch to the cranial base. The following is a partial list:

- **SN Plane** – A line from sella to nasion – considered to represent the cranial base.
- **Frankfurt Horizontal Plane** – Porion to Orbitale (Bony)
- **Camper's Plane** – Acanthion-external auditory meatus plane (Bony)
- **OPPMI Plane** - Odontoid Process – Pterygomaxillary Fissure – Incisive Foramen (Bony)
- **HIP Line** – Hamular Notch – Incisive Papilla (Soft Tissue) – "Transit Line Plane"
- **Ala- Tragus Line** – Ala of nose to tragus of ear (Soft Tissue)
- **Many others**

All these references change over time based on research.

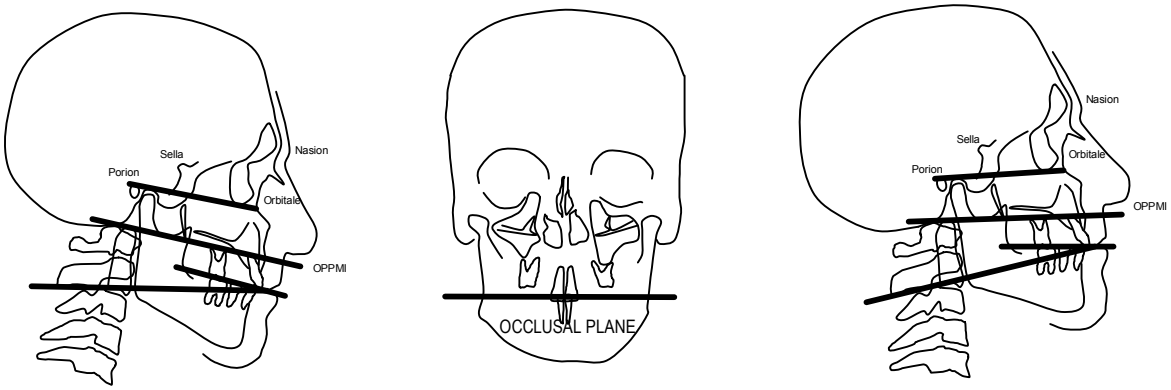

Physiologic Occlusal Plane Frontal View Pathologic Occlusal Plane

Figure 1

Inclination of the Occlusal Plane (IOP)

The most common plane used is Frankfurt plane (porion-orbitale). It was first conceived for the orientation of skulls in anthropology in the late nineteenth century. Ferrario (1994), in previous studies have shown that in natural head posture (NHP), the Frankfurt plane is extended, with the orbitale higher than the tragus or transverse horizontal axis. Men showed an upward tendency and females showed a downward tendency. This study implied an overly steep angulation of the occlusal plane with the incisal edges of the maxillary anteriors placed inferiorly when compared to NHP. <1> It was concluded that the two Frankfurt planes were never coincident in all subjects; the tragus was always lower and more anterior than the porion.
On average, the angle tragus-orbitale-porion was about 6°.

Ciancaglini (2003) when comparing 14 healthy versus 14 TMD young adults with normal occlusion reported:

- *No significant deviation from the horizontal was observed for the interpupillary axis and occlusal plane.*
- *In lateral view, the Frankfurt plane was upward-orientated relative to the true horizontal in TMD group* (mean angular deviation 2.8 degrees, 95% CI, 1.0-4.6 degrees).
- *The occlusal and Camper planes were* <u>*downward-orientated*</u> *in* <u>*both*</u> <u>*groups*</u> ($P < 0.0001$)
- *Inclination of occlusal plane* <u>*tended to be smaller in TMD subjects*</u> (mean difference between groups, -3.8 degrees, 95% CI, -7.6-0.1 degrees).
- Furthermore, data suggests, within this population, *TMD might be mainly associated with head posture rather than with craniofacial morphology.* **<2>** See Figure 1.

The Journal of Prosthodontic Dentistry has reported Camper's Plane (Acanthion-external auditory meatus plane, boney) is frequently used for the purpose of establishing the ala tragus plane. Ideally, the ala-tragus plane is considered to be parallel to the occlusal plane. "The occlusal plane is at an angle of approximately 10 degrees relative to the Frankfort horizontal plane". <3>

The Journal of Prosthodontics also reported:

1. The inclination of the occlusal plane (IOP) is one of the key factors governing occlusal balance.
2. Determination of IOP is an important step before equilibrating complete dentures, comprehensive restorative dentistry and orthodontic procedures. <4>

Chan (2002, 2005) demonstrated by computerized mandibular scanning (CMS), EMG signaling before and after TENS and with ICAT radiographic imaging that as the mandible moves anterior along an optimized isotonic path of closure the head tilt's downward, thus changing the orientation of the occlusal plane from a flatter occlusal plane (pathologic) as referenced from a horizontal level baseline to a more angled (6 degrees) occlusal plane (physiologic).

Eye Posture, Head Posture & Maxillary-Mandibular Positioning

Dental literature has often used the horizontal level as a reference for analysis of the occlusal plane both in the frontal and sagittal/lateral views, bipupilar plane, otic plane, as well as head posture. The orientation of the maxillary cast should be accurately reproduced clinically and transferred to the laboratory technician's occlusal analyzing table at the bench both referenced to horizontal level.

Vision plays a significant role in balance. Approximately twenty percent of the nerve fibers from the eyes interact with the vestibular system. The inter-pupillary orientation of the eyes should be centered within the orbits of the cranium when the cervical neck and head posture is normalized. The eyes are key sense organs to assist in coordinated balance control and spatial relationships maintenance of the human body.

In an effort to adjust to the vertical misalignment of the eyes, the person will frequently tip their head to mechanically help align the eyes. This may often be a result of a posterior mal-alignment of the mandible to the cranium (see figure 2). This in turn can cause a tilting up of the head and

posteriorizing of the mandible. Ear congestion feelings, resultant dizziness and balance disorders can result.

Figure 2

Otic plane relates to the sense of balance and equilibrium because it relates to the semicircular canals. This sense of equilibrium allows us to know the position of the head in space and to the rest of the body. Mechanoreceptors in the cervical spine and mandible will react to changes in the cranial, cervical and mandibular posture in an attempt to keep these horizontal relationships intact.

Occlusal Plane Determination

Traditionally most restorative aesthetic clinicians have paid more attention to the frontal horizontal plane axis (interpupillary, otic and frontal occlusal) as they related to the long axis of the face. The use of the classic stick bites and symmetry bites have been used to capture these two dimensional relationships to register the frontal horizontal levelness of their patients maxillary arches. This visual subjective assessment by the dentist has been used as a standard reference check to determine the maxillary arch levelness frontally for years when communicating with the laboratory technician.

Although this may help aid the technician to mount the maxillary cast in the frontal horizontal planes, it fails to give an accurate relationship in the sagittal or lateral axis, especially when realizing that it is the posterior occlusal plane slant (pitch axis) that is critical when designing the curvature and angle of the smile line (bicuspids to molars) as referenced to the surrounding lip borders of the oral cavity.

Figure 3: Note the left and right occlusal plane slant of the above patient when seen from the lateral view (referenced to horizontal level).

Most laboratory technicians have found that when using these devices that the maxillary mountings often did not match the accompanying frontal smile photographs. With years of laboratory mounting experience, the technician customarily set the stick bite aside and mounted the maxillary cast to match the photograph in the frontal plane by their trained eyes. Further, it left in question the angle or slant of the posterior occlusal plane (pitch axis) as it related to the sagittal horizontal plane relative to a level table.

One of the most important objectives in maxillary mounting is to replicate the maxillary teeth orientation as it is seen sagittally/laterally from the side view of the patient. *This side view of the occlusal plane can be easily observed when asking the patient to smile with their head at horizontal level with the pupils of the eyes centered of the orbits looking at the horizon (straight ahead) and pronouncing the letter "E".*

This occlusal plane angle is critical for optimal smile designing and must be accurately captured to correctly mount the maxillary cast, referencing it to the horizontal occlusal analyzing table for proper occlusal plane analysis.

Diagnosing the Maxillary Cast Mountings

The maxillary cast mountings can be very diagnostic as to indicate whether there exists unresolved cranial to mandibular muscular imbalances. When the head position and eye orientation within the orbits are in a pathologic position an accommodative response will result in a forward head posture (effecting the cervical spine relationship – kyphosis) with an accompany "abnormal mandibular jaw closure pattern" (G. Wolford). The head tilt will be upward contributing the cervical neck aches and pain with an anatomically flatter to an upward anterior slanting occlusal plane as referenced from horizontal level (Figure 1). ICAT radiographic scans will confirm that the boney reference from the odontoid process through the pterygomaxillary fissure and anterior to the incisive foramen will be abnormally level. Thus, when mounting the maxillary cast via the comparable hamular-incisive papilla (HIP) soft tissue references it will present as a very flat to anteriorly upward pitched occlusal plane (57.6%). <5>

Patient's who are neuromuscularly stabilized and cranio-mandibular-cervically balanced will present with a more normalize head posture (head tilt downward), effecting the cervical spine relationship – lordosis, with an accompanying isotonic jaw closure pattern. ICAT radiographic imaging clearly demonstrates (a line through the odontoid process, pterygomaxillary fissure and anterior to the incisive foramen) a downward slant (87.5%). <5> The occlusal plane will also be more parallel to these boney references confirming the HIP reference also slants downward in relationship to horizontal level. This physiologic occlusal relationship must be accurately recorded and represented in the laboratory maxillary mounting if an optimal smile line is to be designed to match nature's occlusal plane. Occlusal-cervical, cranio-mandibular relationships and tooth width-length proportions can be achieved to natures design via visual analysis of the various leveling planes. The trained and experienced laboratory technicians realize these facts.

HIP Plane Before Diagnostic Wax UP

Figure 4: Maxillary cast was mounted to classic HIP soft tissue landmarks. The flat occlusal plane referenced to a horizontal level table would be indicative of a pathologic forward head orientation with underlying unresolved musculoskeletal cranium to mandibular occlusal posture.

OPI (Fox Plane) Before Diagnostic Wax Up

Figure 5: Maxillary cast mounted using the OPI (Occlusal Plane Index/Fox Plane). Notice the occlusal plane slants downward (6 degrees) as referenced to the horizontal table, indicative of a more normalized head posture supported by an optimized mandibular position.

Figure 6:

Before Treatment Occlusal Plane at CO
(Flat) – Level HIP

After Treatment Occlusal Plane at Myocentric
(Angled) – Downward slant HIP

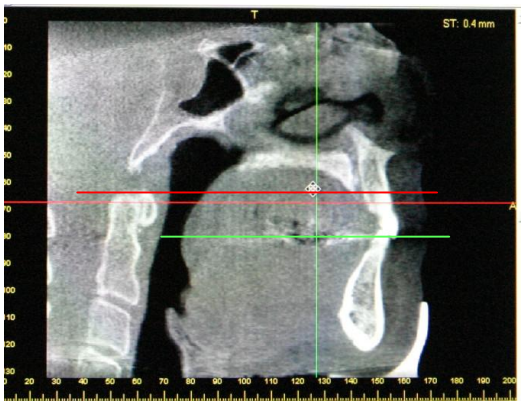

A.

B.

A: ICAT scan shows a level/flat occlusal plane parallel to the boney odontoid-incisive foramen (HIP) before neuromuscular stabilization (pathologic occlusal plane orientation). Patient is unposed, at the habitual centric occlusal mandibular posture.

B: ICAT scan shows a more normalized downward slant boney odontoid-incisive foramen (HIP) occlusal plane after neuromuscular orthotic treatment (physiologic occlusal plane orientation), at an optimized myocentric occlusal mandibular posture.

Figure 7

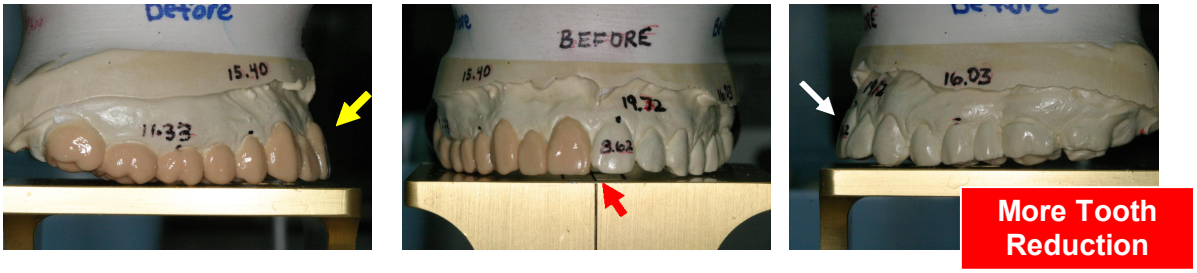

A: HIP Plane Mount and Diagnostic Wax Up – Note the shorter upper posterior teeth with built in curve of Spee. Central incisors are waxed off the level table to compensate to create a proper tooth length and width. Emergence profile of maxillary central incisor will be more pronounced.

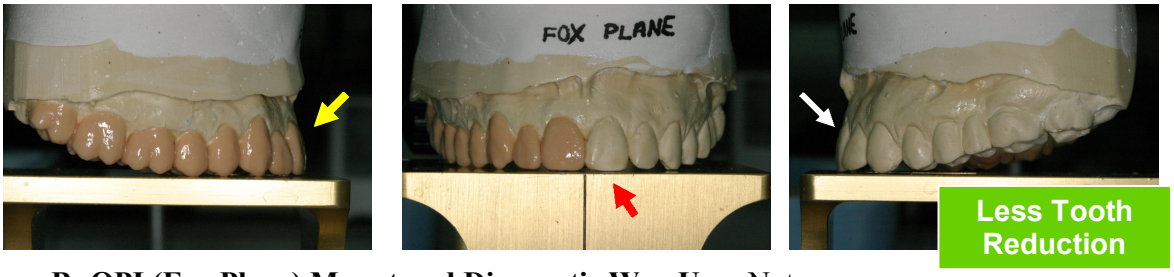

B: OPI (Fox Plane) Mount and Diagnostic Wax Up – Note a more normalized posterior crown length also with a built in curve of Spee. Maxillary central incisor root angulation is more idealized. The central incisor length and width is referenced from the occlusal analyzing table and waxed as indicated without compensating the anterior incisor wax up from the level table.

Recording the Occlusal Plane Angle with the OPI Using A Fox Plane

A simple and reasonable clinical technique using the well known Fox Plane (Dentsply, Trubyte) can be used to record the maxillary arch with the patients head at horizontal level (Figure 8).

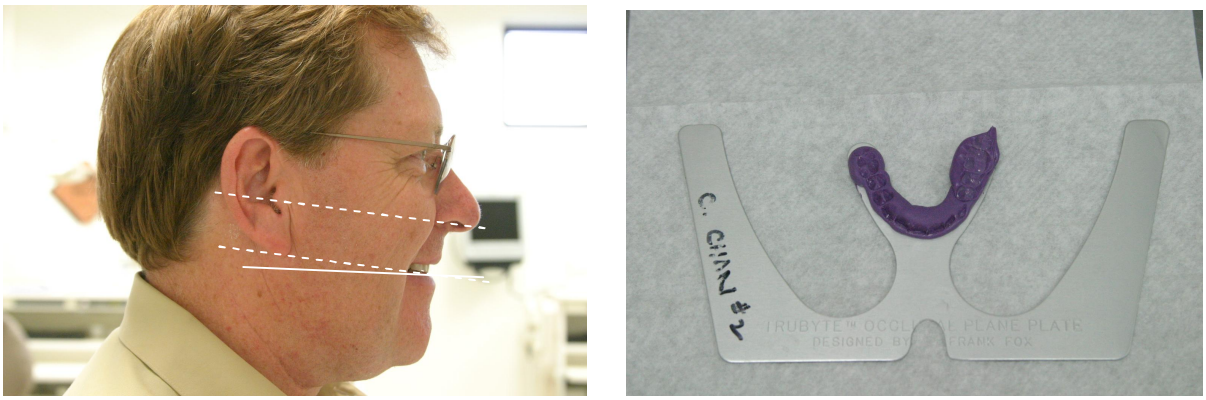

A **B**

Figure 8

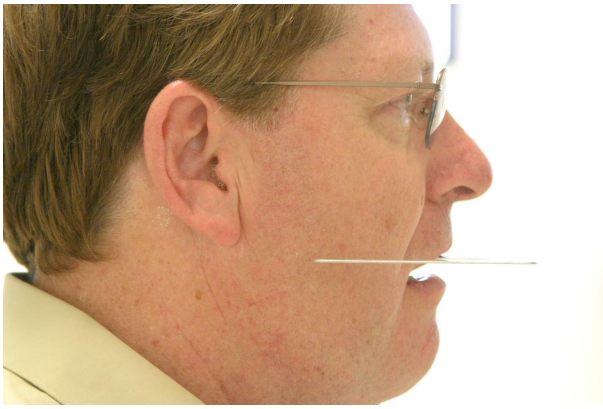

A

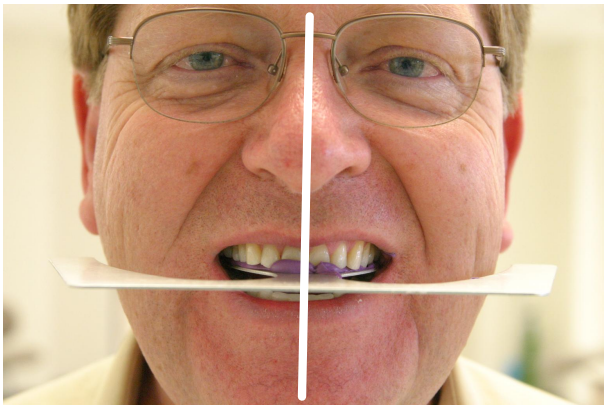

B

Figure 9

Clinical Technique – *This Is How I Do It*

1. First – with the patient standing straight and the head positioned with eyes looking straight ahead looking at the horizon, make sure the sagittal head tilt is with the eyes in the center of the orbits. (Natures leveling bubbles). This will assist in getting the head correctly oriented to level. Subjectively assess the long axis of the face. The interpupillary eyes should not be used alone to reference to frontal horizontal level, since some patient's eyes may be different from one side to the other. Ear levelness, eye brow heights, nose orientations and corner of the lips may not always be reliable references for facial symmetry.

2. Syringe any fast set polyvinyl (30 second bite registration material) on the Fox Plane bite fork and insert it into the mouth upward against the maxillary anterior teeth. *Do not press the posterior region of the bite fork up on the upper posterior occlusal surfaces!* It is important to have the patient keep their head level when opening the lower jaw and the eyes looking straight ahead. Check to confirm the pupils are centered of the eye sockets/orbits). See Figure 9A.

3. Orient the Fox Plane to level and perpendicular to the long axis of the face as well as level sagittally/lateral level to the ground (Figure 9B).

4. Allow the polyvinyl material to set firm while holding Fox Plane with light finger pressure anteriorly. Take a moment to confirm frontal and sagittal levelness to the ground. If the recording does not look right repeat the above steps until correctly leveled and recorded. After the PV material hardens, remove the Fox Plane and occlusal plane index (OPI) from the mouth.

5. Peal away the PV occlusal plane index (OPI) from the Fox Plane bite fork and place the OPI on any level mounting table and oriented it to the center/midline. (Orienting the Fox Plane with the OPI directly on the analyzing table for mounting can also be done). Place the upper dental cast into the index registration and mount the upper cast.

6. After the upper cast is set and mounted remove the OPI from the mounting table and evaluate the occlusal table slant or angulation (pitch) as it relates to the horizontal table.

7. Mount the lower cast to the upper via the Myocentric bite registration.

Now you have the upper and lower casts mounted physiologically and accurately, relating the patient's maxilla and mandible on any articulating "model holder".

Occlusal Plane Index (OPI)/ Level Fox Plane

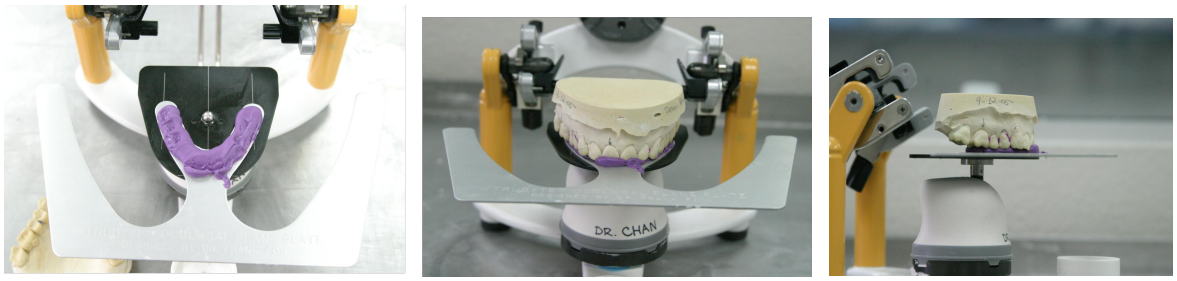

Figure 10 A

Figure 10 B: Note - pre treatment diagnostic casts indicate a 5-6 degree occlusal plane angle.

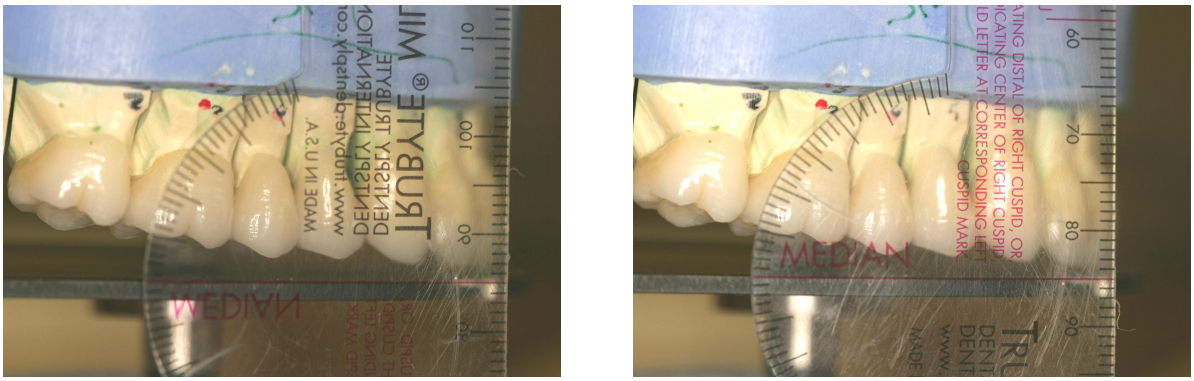

OPI gives the laboratory an easy starting reference to build the crowns with 6 -10 degree occlusal plane with little pre operative stone model occlusal reduction. Altering the level occlusal table at the bench is no longer necessary to create the proper posterior crown length.

Figure 11

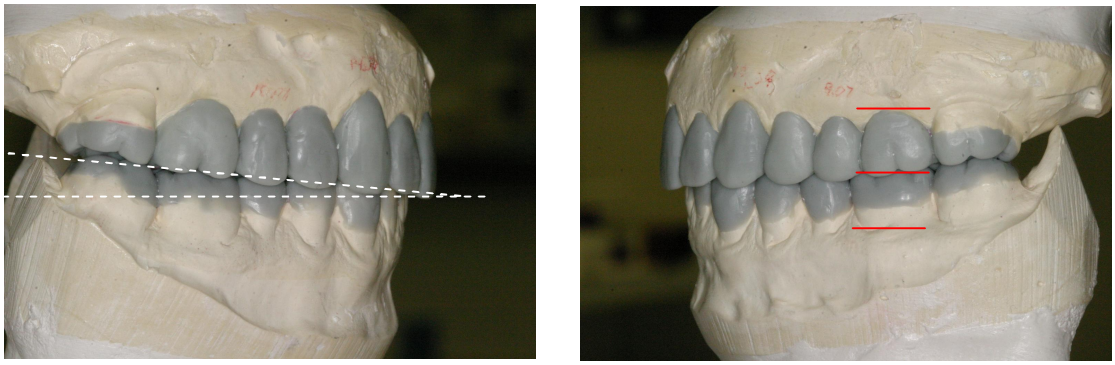

A. **B.**

A. A six degree slant of the occlusal plane referenced from horizontal level is easily waxed with curve of Spee and curve of Wilson to artistically create a soft smile line. B. Note a more even distribution of the upper and lower crown length in the posterior region due to proper occlusal plane determination and recording with the OPI (Fox Plane).

Figure 12

Figure 13: A soft gentle smile line is created based on an optimized mandibular position and a properly mounted maxillary cast mount via the OPI (Fox Plane) technique (not based on a soft tissue HIP mount/ flat, see Figure 6 – before and after ICAT).

Figure 14: Left: Before treatment smile: Note the maxillary frontal plane downward left cant. Right: Maxillary finished restorations. Note the corrected occlusal smile line.

Before Treatment

After Treatment

Finished maxillary restorations

The patient selected shade 110, 040, 030 from Ivoclar's Chromoscope shade guide. Heavy translucency at the incisal third along with a gradual transition to the gingival and proximal. The natural surface texture is created to give realism alone with internal sculpted dentinal lobes.

Conclusion

The Occlusal Plane Index (OPI)/ Fox Plane is a simple technique to effectively record the maxillary occlusal plane angle (slant) for a more accurate diagnostic mount and evaluation when referenced to any horizontal occlusal table analyzer. Kois, Leary, Jankelson, and others have used versions of the Fox Plane to align the maxillary arch successfully for years. This technique is designed to better assess the maxillary occlusal cants, asymmetries and occlusal discrepancies when referenced to the horizontal ground when the patient's head is correctly oriented looking at a level horizontal position. It assists both the dentist and laboratory technician to better communicate a more representative occlusal plane orientation for occlusal waxing and smile design. It is a simple and inexpensive technique to use, allowing an easy accurate transfer to any occlusal analyzing table via the OPI. It minimizes guessing and a need to alter the occlual pitch or angle of the occlusal plane in the laboratory. It allows for a more proportional distribution and crown length ratio between the upper and lower posterior crowns and prevents the need to excessively reduce the maxillary posterior occlusion during crown preparation.

Dr. Clayton A. Chan *is dedicated to share his passion and teaches the neuromuscular principles that have worked for him. He is an educator to thousands of dentist all around the world, inspiring them to take their practices to another level. He is considered by many an authority on Neuromuscular Dentistry and Occlusion. He practice's in Las Vegas, Nevada where he focuses on Aesthetic Dental Orthopedics, orthodontics and TMJ, implementing both the gnathological and neuromuscular principles. He is Director of Neuromuscular Dentistry at the Las Vegas Institute for Advanced Dental Studies.*

References:

1. Braun S, Legan, HL: Changes in occlusion related to the cant of the occlusal plane. Am J Orthod Dentofacial Orthop. 1997 Nov; 112 (5):17A-20A.

2. Virgilio F. Ferrario, MD, Chiarella Sforza, MD, Domenica Germanò, MD, Luca L. Dalloca, DMD, Alessandro Miani Jr., MD: Head posture and cephalometric analyses: An integrated photographic/radiographic technique, *The Journal of Prosthetic Dentistry,* Volume 106, Number 3, September 1994.

3. Ciancaglini R, Colombo-Bolla G, Gherlone EF, Radaelli G.: Orientation of craniofacial planes and temporomandibular disorder in young adults with normal occlusion. *J Oral Rehabil.* 2003 Sep;30(9):878-86.

4. The Glossary of Prosthodontic Terms, Seventh Edition (GPT-7), *The Journal of Prosthodontic Dentistry,* Volume 81, Number 1, January 1999.

5. The Inclination of the Occlusal Plane, *J. Prosth. Dent*., Volume 87, Number 2, February 2002.

6. Investigative Clinical Research for Neuromuscular Dental Technology: HIP Research Investigative Study, Four studies - March 2004, October 2004, May 2005 and June 2005. 82 participating dental laboratory technicians, 154 maxillary model casts, Las Vegas Institute for Advanced Dental Studies, Las Vegas, Nevada.