

TREATMENT SCANS THAT CHANGE THE DIAGNOSTIC PHASE INTO OCCLUSAL TREATMENT

August 18, 2002

Clayton A. Chan, D.D.S., F.I.C.C.M.O.

“The Main Thing is to Keep the Main Thing the Main Thing” – Dr. Steven Covey

With the advent of computerization and the capacity to record, scrutinize, and analyze gross as well as fine mandibular movements, joint sound and masticatory muscle activity, the clinician is challenged to decipher the abundance of gathered data. Those dentist that are using this technology are faced with the need to distinguish between diagnostic data, interpret the data and transition that information into meaningful clinical treatment. Much of the data gathering process has been mainly directed at diagnostic information. Patient care and meaningful treatment is the goal of any clinical dentist who gathers diagnostic data to appropriately interpret all the relevant information into meaningful treatment in the operatory.

Technological advances have been developed for the clinical dentist to see muscle responses come alive as they relate to mandibular positioning and occlusion. With these objective and dynamic measuring tools the dentist can gather data of physiologic responses and better assess and monitor his/ her patient in a manner that surpasses traditional manual manipulative techniques. It is now possible to assess objectively whether treatment is effective or not effective, when a bite relationship is optimal or not, but data must be understood and interpreted. The dynamics of mandibular movements and the status of the masticatory muscles have now come alive through electromyography and computerized mandibular scanning!

Computerized Mandibular Scanning (CMS) - measures jaw movements and locates mandibular position in space giving the clinician new insights into the stomatognathic system that have been unseen by traditional occlusal approaches.

Surface Electromyography (EMG)- measures the status of muscle giving new understanding to the importance of mandibular positioning and the health of the masticatory muscles.

Electrosonography (ESG) – measures high and low frequency joints sounds.

Ultra Low Frequency Transcutaneous Electroneural Stimulation Myomonitor (TENS) – physiologically relaxes the masticatory muscles via neural stimulation of the trigeminal (V) and facial (VII) cranial nerves synchronously and bilaterally.

Although there are many scans that indirectly or directly relate to the diagnostic picture for treatment of many musculoskeletal occlusal problems, they are none the less only

diagnostic in nature. The diagnostic scans are: scans 2, 3, 4/5, 6, 8, 9, 10, 11, 12, 13, and 18 (Myotronics K7 Kinesograph, Tukwila, WA). All scans, but scan 4/5, 8, and 12 are scans that can be used in a treatment modality. Many of the listed scans do not physically change the patient's perception of their problem and neither do they directly add to the patient's actual treatment outcomes. The patient presenting with various musculoskeletal occlusal problems comes to the dentist for treatment, not just for a diagnosis.

The ability to interpret the diagnostic data and understand whether there are intracapsular or extracapsular joint problems, whether there is hyperactive or isotonic muscle activity during mandibular rest or function, or whether there are mandibular deviations or deflections is of diagnostic interest to the clinician. The diagnostic data is not intended to change the patient's present status. Diagnostics give insight as to how best to carry out treatment, it gives the clinician an in depth understanding what is being treated and also gives a better treatment direction whether to treat or not to treat. The patient is awaiting appropriate treatment regardless of all the diagnostic data gathered. Data interpretation of these diagnosed problems still must be assimilated toward meaningful patient treatment outcomes.

Today's clinical dentists have discovered among all the various scans available that there are three diagnostic as well as treatment scans that help in accessing physiologic occlusion. Treatment scans are defined as computerized recorded data that has a direct correlation not only as diagnostic information, but information that relates to changing the maxillo-mandibular relationship and/or has a direct correlation to altering the dental occlusion while the clinician is in a treatment mode.

In a clinical setting, treatment scans assist the dentist objectively in identifying:

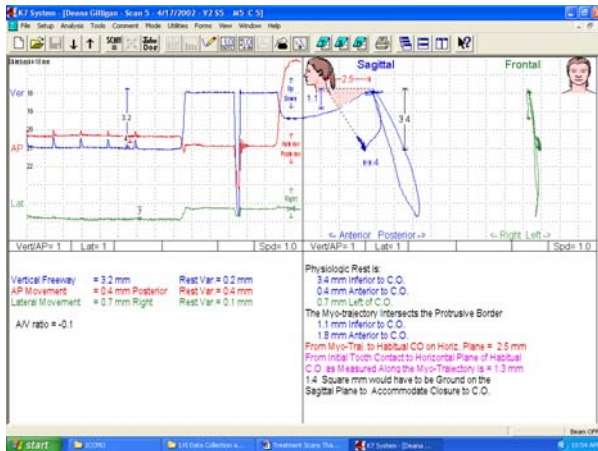
- 1) The physiologic rest position of the mandible, a starting point for any comprehensive occlusal treatment,
- 2) Isotonic path of mandibular opening and closure on a neuromuscular trajectory, critical when determining the antero-posterior relationship of the maxillary to mandibular occlusion, and
- 3) Balanced centric terminal contacting occlusion and mandibular torque during function.

Scans that have direct correlation to mandibular positioning (i.e., bite registration), and occlusal changes (i.e., coronoplasty) are treatment scans that actually transition objective gathered data into patient treatment. These types of scans can now be added to the clinician's treatment tool box bringing significance and practicality to clinical dentistry.

TREATMENT SCANS – SCAN 4/5, 12 AND 8

Many of the leading clinicians are recognizing that having technology that not only documents, but more importantly assists in "effective patient treatment" enhances their successes as expert treating clinicians in the restorative and TMD arena. It should be

noted that all diagnostic data and diagnostic scans are pertinent toward a thorough comprehensive diagnosis as well as an effective treatment protocol.



Treatment Scan 4/5 – Records the Sagittal and Frontal perspective of mandibular movements in both the vertical, antero-posterior and lateral.

Once the clinician has completed the diagnostic phase, a treatment phase begins. The clinician soon recognizes that objective data during the clinical treatment process may be of significant help in decision making as to: Where to take the bite? What position should the mandible be positioned for optimal stabilization or bite registration? What vertical or AP position is optimal when modifying the occlusion? Which tooth is the offending tooth that needs to be occlusally adjusted for neuromuscular balance? Treatment scans can be used during this phase of treatment to assist the doctor in delivering a more favorable treatment result. The three treatment scans by Myotronics, scans 4/5, 12 and 8, that I have found to be clinically useful during the patient treatment phase are:

1. **Recording A Bite Registration** – CMS Scan 4/5 is a combined screen displaying both scan 4 and 5 together. It is effective to monitor both the quality of the Myomonitor pulse in the sweep mode (scan 4) with the sagittal and frontal views of mandibular movement (scan 5). A 6 oz. light weight sensor array is used to track mandibular movements in 3 dimensions. Simultaneous live patient mandibular positioning with EMG muscle activity monitoring is used to identify a more optimal mandibular posture when recording a bite registration. To date I have found this to be the most sophisticated yet simple means to taking an optimal bite registration.
2. **Bite Adjustments** - EMG scan 12 is used to refine the patient's occlusion after a physiologically correct antero-posterior and vertical position has first been established. This recording is unique in that it helps the clinician refine the bite beyond observable articulating paper marks, taking occlusal refinement to a higher level of micro-occlusion. Fine premature first tooth contacts and inclines are identified via muscle recordings (high low EMG chart) that eliminate

mandibular torquing and forces which contribute to patient's complaints of unidentifiable tooth sensitivity and aches. This technology takes bite adjustments outside the realm of habitual accommodative occlusal adjustments into the realm of physiology for dental health.

3. **Post Treatment Evaluation for Patient Comfort** – Scan 8 displays the quality of chewing patterns of the patient. It can be monitored by both the doctor and clinical staff to assess precision of terminal centric occlusion, muscle balance and jaw positioning during function. A dynamic mandibular tracking of jaw movements using Scan 8 is a simple visual recording to better evaluate the precision of the finished occlusion and quality of muscle function during the chewing cycle for patient comfort.

Although diagnostic jaw tracking scans and EMG scans are of importance in the diagnostic phase, they only present characteristics that assist the clinician to further visualize the unknown and misunderstood anatomy and physiology.

These clinically oriented scans require training, experience and skill on the part of the clinician to implement the data into actual clinical treatment. With the ability to visualize movements and occlusion at a microscopic level, attention to detail becomes a natural progression toward a refined awareness of how precise occlusion can be. This awareness results in eliminating occlusal guess work, speeding up treatment resolution time, improving effective treatment results, and clinical satisfaction for the patient.

Clinical Realities - Scan 4/5 Bite Registration

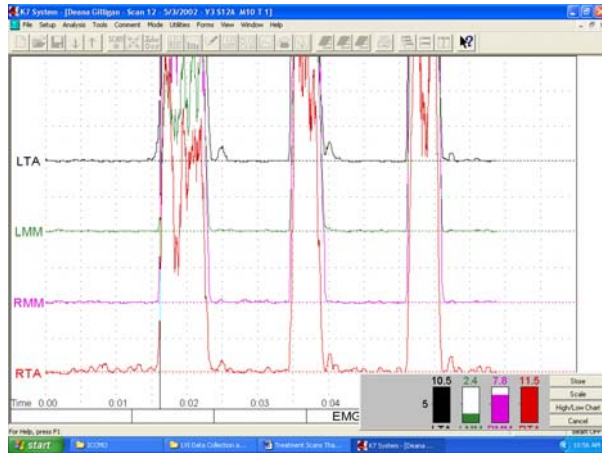Scan 4/5 is the fundamental scan that relays mandibular positioning during and after TENS in relationship to habitual centric occlusion (CO). A neuromuscular trajectory is projected from the mandibles physiologic rest position. This ability to visualize the antero-posterior (AP) position in space gives the treating clinician whether a restorative dentist, TMD dentist or orthodontist, the ability to make a definitive diagnosis as to how best to relate the maxillary and mandibular arches in a physiologic manner. Without this scan definitive treatment cannot be confirmed.

Combining real time EMG recordings with CMS also enhances the ability of the clinician to precisely target a myocentric position when capturing a bite relationship to begin his/her occlusal diagnosis. Any definitive treatment for any restorative, TMD or orthodontic dentistry cannot properly begin a treatment regimen without a comprehensive and precise determination of where a physiologic mandibular relationship exists to the maxilla. Thus, the importance of scan 4/5.

Clinical Realities – Finishing the Bite with Scan 12 (Micro-Occlusion/Coronoplasty)

Once treatment has been rendered to the established myocentric position either with any removable or fixed dentistry, scan 12 can be implemented to better assess a more precise finishing and/ or stabilized position to a terminal contact position for the patient. It is an EMG functional bite/ clench scan that records muscle activity of both the anterior

temporalis and masseter muscles bilaterally during a centric closure pattern. Its main purpose and goal is to identify imbalanced muscle responses and mandibular torque via the high low chart which displays various high low patterns that correspond to a first tooth contact and/ or area during mandibular closure.



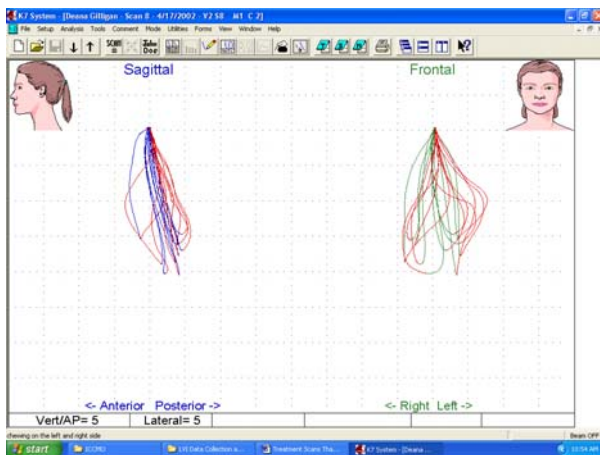
This scan should be used only after removing gross interferences and refining the bite to a point of establishing an even bilateral occlusal contact. (Scan 11, functional clench test, has been used by some to assist in gross occlusal balancing before implementing the more refined scan 12).

Scan 12 is one of the most highly under rated and least understood of all scan among the neuromuscular clinicians including those that treat TMD. Because of our traditional training the lack of in depth awareness of the micro-occlusal concepts has hindered the ability of many clinicians to fully realize successful treatment outcomes of some of the most perplexing TMD cases, only relegating the continued occlusal problem as a psychosomatic problem of the whinying and complaining patient. These continued occlusal complaints have been often dismissed by the dentist as related to other ascending cervical problems, emotional or nutritional imbalances. Based on the clinician's limited awareness and inability to deliver a detailed occlusal treatment the dentist relegates the patient's occlusal complaints as normal and beyond the scope of the dentist care.

Scan 12 is one of the most important treatment scans that can be mastered that allows the clinician to bring masticatory muscle function into balance via measured data of the patient's occlusal perception. Without an occlusion that is neuromuscularly balanced, mandibular occlusal avoidance patterns will develop, further contributing to other associated TMD ascending descending problems that are disassociated by the patient and the treating clinician. Scan 12 is an occlusal finishing treatment scan that brings micro-occlusal adjustment treatment to a higher level. It brings the patient one step closer to a final result to satisfy the patient's distinct proprioceptive needs in calming the neuromuscular system.

Clinical Realities- Scan 8 (Chewing Cycle): A Combined Functional Occlusal Evaluation

Scan 8 displays mandibular chewing patterns in both the frontal and sagittal planes. It is the third powerful tool the neuromuscular clinician has available in the treatment scan armamentarium in evaluating not only muscular balance, but also the preciseness of the established centric contact. This integrated scan, which combines functional mandibular chewing movements with an ability to visualize the quality of the terminal contact in both the sagittal and frontal planes allows the clinician to again confirm and test the accuracy and skill of the dentist regarding any occlusal treatment rendered to the patient's bite position and occlusion.



Occlusal balance on a neuromuscular trajectory will depict itself as an unguarded opening and closing pattern into a precise centric terminal contact position without deflections or deviations. Scan 8 confirms scan 12's precise adjustment qualities in function and also confirms scan 4/5 occlusal position accuracy in function, especially in the AP and frontal planes.

One unique feature of scan 8 is that it is a functional mandibular test of all jaw movements both laterally, vertically and antero-posteriorly, without any programming how the mandible should move and chew. It also displays the patient's chewing patterns and the mandibles ability or inability to move freely without any occlusal deflecting interference.

These three significant "treatment scans" are to be clearly distinguished from all the other diagnostic scans as ones that directly apply to the clinically oriented minded dentist. Mastering the use of each of these high tech scans can bring objective meaning to the effectiveness occlusal restorative and TMD treatment.

Clayton A. Chan, D.D.S., F.I.C.C.M.O. invites you to attend LVI's Comprehensive Occlusal Curriculum to learn how to implement refined occlusion in the aesthetic restorative practice. Dr. Chan is the Director of the Neuromuscular Dental Center, Las Vegas Institute for Advanced Dental Studies.

